

Navajo Neurohepatopathy Is Caused by a Mutation in the *MPV17* Gene

Charalampos L. Karadimas, Tuan H. Vu, Stephen A. Holve, Penelope Chronopoulou, Catarina Quinzii, Stanley D. Johnsen, Janice Kurth, Elizabeth Eggers, Lluís Palenzuela, Kurenai Tanji, Eduardo Bonilla, Darryl C. De Vivo, Salvatore DiMauro, and Michio Hirano

Navajo neurohepatopathy (NNH) is an autosomal recessive disease that is prevalent among Navajo children in the southwestern United States. The major clinical features are hepatopathy, peripheral neuropathy, corneal anesthesia and scarring, acral mutilation, cerebral leukoencephalopathy, failure to thrive, and recurrent metabolic acidosis with intercurrent infections. Infantile, childhood, and classic forms of NNH have been described. Mitochondrial DNA (mtDNA) depletion was detected in the livers of two patients, suggesting a primary defect in mtDNA maintenance. Homozygosity mapping of two families with NNH suggested linkage to chromosome 2p24. This locus includes the *MPV17* gene, which, when mutated, causes a hepatocerebral form of mtDNA depletion. Sequencing of the *MPV17* gene in six patients with NNH from five families revealed the homozygous R50Q mutation described elsewhere. Identification of a single missense mutation in patients with NNH confirms that the disease is probably due to a founder effect and extends the phenotypic spectrum associated with *MPV17* mutations.

Navajo neurohepatopathy (NNH [MIM 256810]) is an autosomal recessive multisystem disorder prevalent in the Navajo population of the southwestern United States. The estimated incidence of the disease in the western Navajo Reservation is 1 in 1,600 live births.¹ Patients with NNH present with liver disease, severe sensory and motor neuropathy, corneal anesthesia and scarring, cerebral leukoencephalopathy, failure to thrive, and recurrent metabolic acidosis with intercurrent illness.¹⁻³ Three phenotypes have been culled on the basis of age at onset and clinical course. The infantile (i.e., onset before age 6 mo) and childhood (i.e., onset between age 1 and 5 years) forms of NNH are dominated by severe hepatopathy and early death from liver failure. The classic form of NNH is characterized by moderate liver dysfunction and progressive neuropathy. Peripheral and CNS demyelination is seen in all three forms. Clinical heterogeneity is illustrated by the occurrence of the three different NNH forms in the same family.¹ To date, the genetic cause of NNH has remained unknown.

The similar clinical, pathological, and biochemical features seen in patients with NNH and in patients with mtDNA depletion syndrome (MDS) suggested that abnormal regulation of mtDNA copy number may be the primary defect in NNH.^{1,3} This concept was confirmed by the documentation of mtDNA depletion in liver biopsies from two patients with NNH.³ This finding, in turn, prompted us to sequence genes associated with MDS in these two patients with NNH, including the genes encoding mitochondrial deoxyguanosine kinase (*DGUOK* [MIM

601465]),⁴ mitochondrial thymidine kinase (*TK2* [MIM 188250]),⁵ succinate-CoA ligase ADP-forming β subunit (*SUCLA2* [MIM 603921]),⁶ and polymerase γ (*POLG* [MIM 174763]),⁷ but we found no pathogenic mutations. The sequencing of another candidate gene that encodes mitochondrial transcription factor A (*TFAM* [MIM 600438]) also failed to reveal any potential mutations.

On the other hand, both historical and demographic data from the Navajo population of the western Navajo Reservation strongly suggested a founder effect as the origin of NNH. In this situation, homozygosity mapping is a powerful tool for the identification of the disease-causing gene. We therefore studied two extended Navajo kindreds in which the disease segregated as an autosomal recessive trait (fig. 1). Three additional nuclear families with NNH were enrolled at a later stage of our study (families 3-5) (fig. 1). Diagnostic criteria for NNH were reported by Holve et al.¹

Family 1 has been described elsewhere^{1,8}: patients V1, V3, and V8 had the infantile, classic, and childhood, respectively, forms of NNH, and patients V11 and V12—two affected brothers of V8—also had classic NNH.¹ During the first year of life, patient 1 (V11) had recurrent hypoglycemia and metabolic acidosis during febrile illnesses. He had poor growth and delayed development; his height and weight were <5th percentile, and he began walking at age 2 years. In school, he had academic difficulties. At age 10 years, he underwent medical evaluation for progressive muscle weakness. His gait was wide-based, and he was unable to run or to hold heavy objects with his hands. Examination revealed greater distal than proximal limb

From the Departments of Neurology (C.L.K.; T.H.V.; P.C.; C.Q.; L.P.; K.T.; E.B.; D.C.D.; S.D.; M.H.), Pathology (K.T.; E.B.), and Pediatrics (D.C.D.), Columbia University Medical Center, New York; Wellspan Neurology, York, PA (T.H.V.); Tuba City Regional Healthcare Corporation, Tuba City, AZ (S.A.H.); Pediatric Neurology Division, St. Joseph's Children's Health Center and the Barrow Neurological Institute (S.D.J.; E.E.), and Visual Technologies LLC (J.K.), Phoenix

Received May 8, 2006; accepted for publication June 12, 2006; electronically published June 28, 2006.

Address for correspondence and reprints: Dr. Michio Hirano, Department of Neurology, Columbia University Medical Center, 630 W. 168th Street, P&S 4-443, New York, NY 10032. E-mail: mh29@columbia.edu

Am. J. Hum. Genet. 2006;79:544-548. © 2006 by The American Society of Human Genetics. All rights reserved. 0002-9297/2006/7903-0017\$15.00

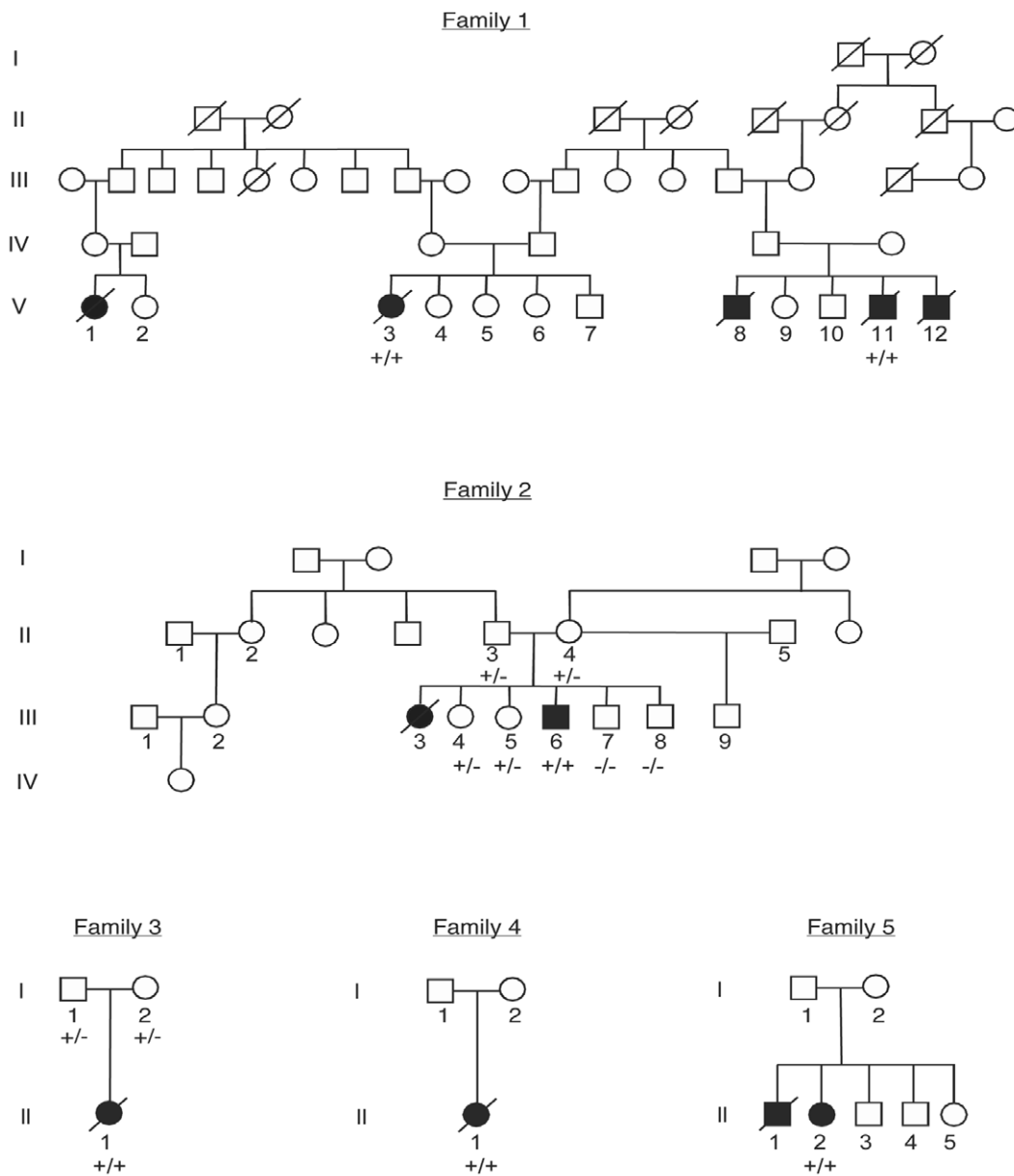


Figure 1. Families 1–5 with NNH. Family 1 was described by Singleton et al.⁸ and by Holve et al.¹ The probands in families 4 (II-1) and 5 (II-1) were reported as patients 1 and 2, respectively, by Vu et al.³ The nucleotide 149G→A transition in the *MPV17* gene is denoted by a plus sign (+), and the normal sequence is denoted by a minus sign (–).

weakness, stocking-glove sensory loss, and areflexia; nerve conduction studies confirmed the presence of a peripheral neuropathy. Muscle biopsy revealed neurogenic atrophy. He did not have corneal ulcerations or scarring. He had no evidence of hepatomegaly or liver dysfunction, but his serum γ -glutamyltransferase (GGT) was mildly elevated. By age 12 years, he had lost the ability to walk and to swallow, which required him to be placed in a chronic care facility, where he was fed through a gastrostomy tube. He developed hepatic cirrhosis and died of liver failure at age 16 years.

As an infant girl, patient 2 (V3) (reported as patient 12 by Holve et al.¹) had recurrent hypoglycemia and meta-

bolic acidosis with febrile illnesses. At age 6 mo, it was noted that she had poor growth and delayed motor development. At age 2 years, when she first walked, she had distal limb muscle weakness, wasting, and areflexia. Nerve conduction studies revealed diffusely slow velocities. Serum transaminases and GGT were two to three times the upper limits of normal, and total and direct bilirubin were mildly elevated. Her weakness worsened and, by age 4 years, she could move only by pulling herself across the ground. Because of distal sensory loss, she had acral mutilation complicated by recurrent skin infections. She also had corneal anesthesia and developed corneal ulcers. Her IQ was 72. Brain magnetic resonance imaging (MRI) re-

vealed diffuse leukoencephalopathy, which was particularly prominent in the cerebellum. By age 16 years, she needed a wheelchair because of her neuropathy and had poor vision due to corneal scarring. At age 20 years, she had hematemesis, and evaluation revealed esophageal varices and cirrhosis. She died of liver failure.

Patient 3 (III-6 in family 2) was reported as patient 17 by Holve et al.¹ This boy had classic NNH. He had an older sister (reported as patient 1 by Holve et al.¹) who died of liver failure at age 1 year and who was presumed to have NNH. In infancy, he had gross motor delay and poor growth; he began walking at age 2 years, and his height and weight were <5th percentile. At age 3 years, he developed corneal ulcerations, and medical evaluation revealed signs of peripheral neuropathy, including loss of corneal sensation, stocking-glove sensory loss, distal limb weakness, and areflexia. Nerve conduction studies revealed marked slowing, and a sural nerve biopsy showed severe loss of myelinated fibers. Blood tests revealed elevated transaminases and GGT but normal bilirubin. At age 4 years, he contracted varicella, which was complicated by liver failure, acute respiratory distress syndrome, metabolic acidosis, and renal dysfunction, but he responded to intensive care. Subsequently, he had persistently elevated transaminases—two to three times the upper limit of normal—and mild elevations of total and direct bilirubin, and his neuropathy progressively worsened. By age 10 years, he was unable to walk or to feed or dress himself. Acral mutilation due to sensory neuropathy caused recurrent infections. He was fed through a gastrostomy tube. Brain MRI revealed leukoencephalopathy. At age 14 years, he had hematemesis due to esophageal varices and cirrhosis. One year later, he died of hepatic failure.

Patient 4 (individual II-1 in family 3) was reported as patient 4 by Holve et al.¹ This girl had infantile NNH and a second cousin (reported as patient 2 by Holve et al.¹ and patient 5 in this report) who received the diagnosis of NNH. At age 6 mo, this infant girl presented with failure to thrive, jaundice, and hepatomegaly. Laboratory studies revealed elevated transaminases, GGT, and total and direct bilirubin. Prothrombin time was prolonged. Liver biopsy showed cholestasis, steatosis, and fibrosis. One month later, she underwent a successful liver transplant. Despite adequate hepatic function, she had recurrent metabolic acidosis and failed to gain weight. Neurological examination revealed hypotonia, distal limb weakness, and gross and fine motor delay. At age 3 years, she was unable to stand without support. She had signs of peripheral neuropathy; pain sensation was absent in her hands and feet, corneal sensation was decreased, distal limb muscles were weak and wasted, and tendon reflexes were absent. Nerve conduction studies revealed slow conduction. Results of a brain MRI were normal. At age 12 years, the patient's donor liver is functioning well, but her height and weight remain <5th percentile, and her peripheral neuropathy continues to worsen.

Patient 5 (II-1 in family 4) had infantile NNH and was

reported as patient 1 by Vu et al.³ She had a second cousin (patient 4 in this report) with infantile NNH. The patient presented at age 1 mo with poor weight gain, and it was noted that she had elevated levels of transaminases and total and direct bilirubin. At age 4 mo, she was evaluated for failure to thrive and was found to have hepatomegaly. A liver biopsy revealed acute hepatocellular necrosis, cirrhosis, and micro- and macrovesicular steatosis. At age 15 mo, she had marked abdominal distention and ascites, muscle wasting, hypotonia, and hyporeflexia. Brain MRI revealed diffuse leukoencephalopathy. One month later, she underwent liver transplantation. Her transplanted liver functioned adequately, but she continued to have failure to thrive and recurrent metabolic acidosis. A feeding gastrostomy tube was placed. At age 2 years, she developed aspiration pneumonia and gram-negative sepsis and died. Subsequent histochemical analysis of liver tissue obtained at transplantation showed COX deficiency and normal-to-increased succinate dehydrogenase activity in most of the hepatocytes.³ Biochemical studies of liver demonstrated decreased activities of respiratory-chain enzyme complexes I, III, and IV (containing mtDNA-encoded subunits) and markedly increased citrate synthase activity.³ Southern blot of liver mtDNA revealed 89% depletion.³

Patient 6 (II-1 in family 5) is a 21-year-old woman with classic NNH and was reported as patient 2 by Vu et al.³ At age 4 mo, she presented with seizures associated with hypoglycemia. Two months later, evaluation for failure to thrive revealed mildly elevated transaminases. Liver biopsies at age 20 mo showed micronodular cirrhosis, mild steatosis, and intracellular glycogen accumulation. At age 11 years, she developed hepatocellular carcinoma and underwent liver transplantation. Although her transplanted liver functioned well, she developed a peripheral neuropathy. Nerve conduction studies showed slow velocities, and brain MRI showed white-matter lesions. Limited studies performed on a small sample of the transplanted liver revealed 82% depletion of mtDNA and, by biochemical analyses, decreased COX but normal citrate synthase activity.³ She had an affected older brother who also had failure to thrive, hypoglycemia, and chronic liver failure and who died at age 5 years from bleeding esophageal varices.

After written informed consent under an institutional review board-approved protocol, peripheral blood was obtained from all patients and unaffected individuals studied. Blood DNA from 2 affected individuals (patients V3 from family 1 and III-6 from family 2) and from 15 unaffected individuals was used for linkage analysis, and genomic DNA extracted from a liver biopsy sample previously obtained from patient V8 in family 1 was also used in our study. All patients met described diagnostic criteria for NNH.¹ A genomewide scan was performed using a set of 400 polymorphic DNA microsatellite markers at average distances of 10 cM (ABI Prism Linkage Mapping Set MD-10 [Applied Biosystems]). The PCR products were run on an ABI Prism 310 Genetic analyzer. Genotypes were iden-

tified using Genescan and Genotyper software (Applied Biosystems). Parametric two-point linkage analyses were performed with the MLINK option of the computer package Linkage, version 5.1, with the assumption of autosomal recessive inheritance with 90% penetrance and a mutation frequency of 1 in 100,000. Allele frequencies were estimated with the haplotypes of all family members included in the study. Recombination frequencies were assumed to be equal in males and females.

The genotype analysis revealed that only one homozygous haplotype, with microsatellite marker *D2S305* at chromosome 2p24.1, was shared by all affected individuals and was either absent or heterozygous in unaffected family members (data not shown). Interestingly, this marker was 1 of only 10 microsatellite markers that gave a pairwise LOD score ≥ 1 (table 1). Further analysis using additional polymorphic DNA markers flanking loci *D3S1263*, *D5S406*, *D7S510*, and *D9S1826* excluded linkage to these loci. On the basis of our microsatellite marker studies, we also excluded mutations in two candidate genes—nuclear respiratory factor-1 (*NRF-1* [MIM 600879]) and mitochondrial endonuclease G (*ENDOG* [MIM 600440])—that are involved in the maintenance of mtDNA copy number.

We then considered other candidate genes around chromosomal locus *D2S305*, a region that contains several genes involved in mitochondrial functions identified through integrative genomics.⁹ One of them was *MPV17* (MIM 137960), which has been recently associated with a new hepatocerebral form of MDS.¹⁰ The close proximity of this gene to our chromosomal locus—and the striking similarities between the phenotype of the described patients with *MPV17* mutations and the clinical picture of infantile NNH—prompted us to perform direct mutation analysis of this gene in our patients. Sequencing revealed a homozygous R50Q mutation in our patients 1–6. Further genetic analysis of all available unaffected individuals confirmed segregation of the mutation with the disease. Taken together, the results of linkage analysis and the detection of the same pathogenic R50Q mutation in patients presenting with the three different forms of the disease show that *MPV17* is the causative gene for NNH. Analysis of additional patients from different families with NNH is needed to explore possible genetic heterogeneity in NNH.

Mpv17 gene insufficiency was produced in mice by a retroviral insert in the genome that decreases its expression.¹¹ Initially, *Mpv17*^{-/-} mice developed glomerulosclerosis. Previous studies suggested a peroxisomal localization of the encoded protein.¹² Subsequently, two homozygous mutations in *MPV17*—R50Q in exon 2 and N166K in exon 7—were identified in four patients with MDS from two families, one of Italian and the other of Moroccan origin.¹⁰ A third patient from a Canadian family was compound heterozygous for R50Q in exon 2 and a 25-bp deletion in exon 7. Functional analysis of the mutations performed in HeLa cells revealed that *MPV17* is involved in mtDNA maintenance and in the regulation of oxidative phosphorylation.¹⁰ Further studies described in the same

Table 1. Two-Point LOD Scores for 10 Microsatellite Markers Identified in a Genomewide Screen of 400 Markers in Families 1 and 2 with NNH

Marker	Chromosome	θ^a						
		.0	.01	.05	.1	.2	.3	.4
<i>D2S2211</i>	2p25.1	1.32	1.27	1.07	.85	.49	.23	.07
<i>D2S305</i>	2p24.1	.98	.95	.84	.69	.42	.21	.06
<i>D2S335</i>	2q33.3	1.04	1.01	.86	.68	.39	.18	.06
<i>D3S1263</i>	3p25.3	1.21	1.18	1.06	.92	.62	.36	.15
<i>D4S1572</i>	4q24	.98	.95	.85	.72	.47	.24	.07
<i>D5S406</i>	5p15.32	1.42	1.38	1.20	.97	.55	.25	.08
<i>D7S510</i>	7p14.1	1.13	1.08	.92	.73	.42	.20	.06
<i>D8S272</i>	8q24.23	1.11	1.07	.90	.69	.37	.17	.07
<i>D9S1826</i>	9q34.3	1.20	1.16	1.02	.85	.54	.28	.10
<i>D10S189</i>	10p14	1.09	1.06	.93	.77	.49	.26	.09

^a Two-point LOD ≥ 1.0 at $\theta = 0$ for all 10 markers.

report¹⁰ indicated that the encoded protein is localized in the inner mitochondrial membrane and that *Mpv17*^{-/-} mice had depletion of mtDNA in liver, similar to the human disease.

NNH is a well-defined clinical entity. The overlapping clinical features of the three forms seem to form a spectrum with an age-related transition from the devastating infantile to the predominantly classic to the more benign and slowly progressive neuropathic forms.^{1,8} It is unclear why some patients succumb to hepatic failure in infancy. With successful liver transplantations, patients with infantile NNH (e.g., patients 4 and 5 in this report) develop progressive peripheral neuropathy and CNS leukoencephalopathy similar to the patients with classic NNH. Because of the inevitable progression of neurological dysfunctions, liver transplantation has very limited value in treatment of this disease. Neuropathy, a salient diagnostic feature of NNH, is not common in other forms of infantile MDS. Only patients with the benign, later-onset myopathic form of MDS due to *TK2* mutation and patients with Alpers syndrome (MIM 203700) and *POLG* mutations show subclinical neuropathy.

The phenotype of the six patients with MDS described by Spinazzola et al.¹⁰ resembles one end of the NNH clinical spectrum that is dominated by lethal early-onset hepatopathy. Two of four affected infants in the Italian family who had the same homozygous R50Q mutation as our patients with NNH died before age 9 mo. Similar courses were seen in patients 2-4 and 3-1 in the same report.¹⁰ Notably, the two surviving patients harboring a homozygous R50Q mutation developed multiple brain lesions and had delayed growth, both typical symptoms of NNH.^{13,14} On the other hand, patient 4-1 developed progressive spinocerebellar ataxia, myoclonus of hands and feet, mental retardation, and severe neurogenic kyphoscoliosis, which are not among the clinical features of NNH. Interestingly, the prolonged survival of this patient to age 9 years, which was achieved by dietary control for hypoglycemia, may have therapeutic implications for patients with the infantile and childhood forms of NNH.

This phenotypic variability suggests that additional neurohepatocerebral forms of MDS may be caused by mutations in *MPV17* in non-Navajo patients. Alternatively, the prominent peripheral nervous system involvement in NNH may indicate that additional unlinked modifier genes or epigenetic factors play a role in the determination of the phenotype.

Liver samples from two patients with NNH have been assessed for mtDNA depletion and respiratory-chain defects. Both showed marked depletion (89% and 82% reductions relative to controls) and corresponding reduced activities of respiratory-chain complexes with mtDNA-encoded subunits. Because liver from one patient with infantile NNH and from another with the classic form have been the only ones studied, it is not possible to correlate the severity of the mitochondrial defects with the NNH subtypes. It is noteworthy that the mtDNA depletion in liver of patients with NNH is similar to that observed in liver of patients with Alpers syndrome (60%–97% mtDNA depletion) due to *POLG* mutations,^{15–17} with hepatocerebral disease due to *DGUOK* mutations (61%–98% mtDNA depletion),^{4,18} and with hepatic disease due to *MPV17* mutations (>70% mtDNA depletion).¹⁰

In conclusion, we identified, by homozygosity mapping, the genetic defect causing NNH, showing that a single mutation in exon 2 of *MVP17* accounts for the different forms of the disease. The identification of *MPV17* as the disease-causing gene will provide a definitive pre- and postnatal diagnosis of NNH and will shed light on the pathogenic mechanism of the disorder.

Acknowledgments

This work was supported by National Institutes of Health grants NS11766 and HD32062, by a grant from the Muscular Dystrophy Association, and by the Marriott Mitochondrial Disorder Clinical Research Fund and the Colleen Giblin Foundation.

Web Resource

The URL for data presented herein is as follows:

Online Mendelian Inheritance in Man (OMIM), <http://www.ncbi.nlm.nih.gov/Omim> (for NNH, *DGUOK*, *TK2*, *SUCLA2*, *POLG*, *TFAM*, *NRF-1*, *ENDOG*, *MPV17*, and Alpers syndrome)

References

- Holve S, Hu D, Shub M, Tyson RW, Sokol RJ (1999) Liver disease in Navajo neuropathy. *J Pediatr* 135:482–493
- Appenzeller O, Kornfeld M, Snyder R (1976) Acromutilating, paralyzing neuropathy with corneal ulceration in Navajo children. *Arch Neurol* 33:733–738
- Vu TH, Tanji K, Holve SA, Bonilla E, Sokol RJ, Snyder RD, Fiore S, Deutsch GH, DiMauro S, De Vivo D (2001) Navajo neurohepatopathy: a mitochondrial DNA depletion syndrome? *Hepatology* 34:116–120
- Mandel H, Szargel R, Labay V, Elpeleg O, Saada A, Shalata A, Anbinder Y, Berkowitz D, Hartman C, Barak M, Eriksson S, Cohen N (2001) The deoxyguanosine kinase gene is mutated in individuals with depleted hepatocerebral mitochondrial DNA. *Nat Genet* 29:337–341
- Saada A, Shaag A, Mandel H, Nevo Y, Eriksson S, Elpeleg O (2001) Mutant mitochondrial thymidine kinase in mitochondrial DNA depletion myopathy. *Nat Genet* 29:342–344
- Elpeleg O, Miller C, Hershkovitz E, Bitner-Glindzicz M, Bondi-Rubinstein G, Rahman S, Pagnamenta A, Eshhar S, Saada A (2005) Deficiency of the ADP-forming succinyl-CoA synthase activity is associated with encephalomyopathy and mitochondrial DNA depletion. *Am J Hum Genet* 76:1081–1086
- Naviaux RK, Nguyen KV (2004) *POLG* mutations associated with Alpers' syndrome and mitochondrial DNA depletion. *Ann Neurol* 55:706–712
- Singleton R, Helgeson SD, Snyder RD, O'Conner PJ, Nelson S, Johnsen SD, Allanson JE (1990) Neuropathy in Navajo children: clinical and epidemiologic features. *Neurology* 40:363–367
- Calvo S, Jain M, Xie X, Sheth SA, Chang B, Goldberger OA, Spinazzola A, Zeviani M, Carr SA, Mootha VK (2006) Systematic identification of human mitochondrial disease genes through integrative genomics. *Nat Genet* 38:576–582
- Spinazzola A, Viscomi C, Fernandez-Vizarrá E, Carrara F, D'Adamo P, Calvo S, Marsano RM, Donnini C, Weiher H, Strisciuglio P, Parini R, Sarzi E, Chan A, DiMauro S, Rotig A, Gasparini P, Ferrero I, Mootha VK, Tiranti V, Zeviani M (2006) *MPV17* encodes an inner mitochondrial membrane protein and is mutated in infantile hepatic mitochondrial DNA depletion. *Nat Genet* 38:570–575
- Weiher H, Noda T, Gray DA, Sharpe AH, Jaenisch R (1990) Transgenic mouse model of kidney disease: insertional inactivation of ubiquitously expressed gene leads to nephrotic syndrome. *Cell* 62:425–434
- Zwacka RM, Reuter A, Pfaff E, Moll J, Gorgas K, Karasawa M, Weiher H (1994) The glomerulosclerosis gene *Mpv17* encodes a peroxisomal protein producing reactive oxygen species. *EMBO J* 13:5129–5134
- Snyder RD, Appenzeller O, Johnson PC (1988) Infantile onset and late central white matter lesions in Navajo neuropathy. *Ann Neurol* 24:327
- Williams KD, Drayer BP, Johnsen SD, Johnson PC (1990) MR imaging of leukoencephalopathy associated with Navajo neuropathy. *AJNR Am J Neuroradiol* 11:400–402
- Naviaux RK, Nyhan WL, Barshop BA, Poulton J, Markusic D, Karpinski NC, Haas RH (1999) Mitochondrial DNA polymerase γ deficiency and mtDNA depletion in a child with Alpers' syndrome. *Ann Neurol* 45:54–58
- Davidzon G, Mancuso M, Ferraris S, Quinzii C, Hirano M, Peters HL, Kirby D, Thorburn DR, DiMauro S (2005) *POLG* mutations and Alpers syndrome. *Ann Neurol* 57:921–923
- Ferrari G, Lamantea E, Donati A, Filosto M, Briem E, Carrara F, Parini R, Simonati A, Santer R, Zeviani M (2005) Infantile hepatocerebral syndromes associated with mutations in the mitochondrial DNA polymerase-gammaA. *Brain* 128:723–731
- Salviati L, Sacconi S, Mancuso M, Otaegui D, Camano P, Marina A, Rabinowitz S, Shiffman R, Thompson K, Wilson CM, Feigenbaum A, Naini AB, Hirano M, Bonilla E, DiMauro S, Vu TH (2002) Mitochondrial DNA depletion and *dGK* gene mutations. *Ann Neurol* 52:311–317